Cancer and Clinical Oncology; Vol. 5, No. 1; 2016
ISSN 1927-4858 E-ISSN 1927-4866
Published by Canadian Center of Science and Education

Soft Tissue Lymphoma Mimicking a Lipomatous Tumor on Fine Needle Aspiration: A Diagnostic Pitfall

Mustafa Yousif[1], Shadi A. Qasem[1], Michael W. Beaty[1] & Simon Bergman[1]

[1] Department of Pathology, Wake Forest School of Medicine, Winston Salem, NC, USA

Correspondence: Shadi A. Qasem, Department of Pathology, Wake Forest Baptist Medical Center, Medical Center Blvd., Winston Salem, NC 27157, USA. Tel: 1-336-716-2640. Fax: 1-336-716-7595. E-mail: sqasem@wakehealth.edu

Received: February 22, 2016 Accepted: April 6, 2016 Online Published: April 19, 2016

doi:10.5539/cco.v5n1p73 URL: http://dx.doi.org/10.5539/cco.v5n1p73

Abstract

Primary soft tissue lymphoma is very rare. Herein we describe a case of a previously healthy patient with a tumor presenting clinically as a soft tissue mass and suspected to be a soft tissue sarcoma on magnetic resonance imaging (MRI). This was initially diagnosed as an atypical lipomatous tumor on fine needle aspiration (FNA) biopsy; however, surgical excision confirmed the diagnosis of diffuse large B-cell lymphoma (DLBCL). The purpose of this report is to emphasize this potential diagnostic pitfall and describe briefly the cytologic features of soft tissue lymphoma.

Keywords: lymphoma, soft tissue, fine needle aspiration, lipomatous tumor, diagnostic pitfall

1. Introduction

Soft tissue lymphoma is rare and accounts for only 0.1-2% of all soft tissue tumors (Damron, Le, Rooney, Vermont, & Poiesz, 1999; Meister, 1992), mostly occurring in middle-age or elderly people (Chan, 2003). Lymphoma can involve any part of the musculoskeletal system. It is most commonly seen involving extremities and especially the lower limbs (Malloy, Fishman, & Magid, 1992; Travis, Banks, & Reiman, 1987). Almost all cases are non-Hodgkin lymphoma (NHL) and the majority are B-cell type. The most common histological subtype is diffuse large B-cell lymphoma (DLBCL) (Yang, Zhang, Fang, Ye, Lin, & Han, 2010; Derenzini, Casadei, Pellegrini, Argnani, Pileri, & Zinzani, 2013; Salamao, Nascimento, Lloyd, Chen, Habermann, & Strickler, 1996). Given the anatomic site of involvement, soft tissue lymphoma may be confused with more common soft tissue tumors/sarcomas (Gao et al., 2012; Gaitonde, Patel, Alagiozian-Angelove, Kadkol, & Peace, 2008; Wakely, Frable, & Kneisl, 2001).

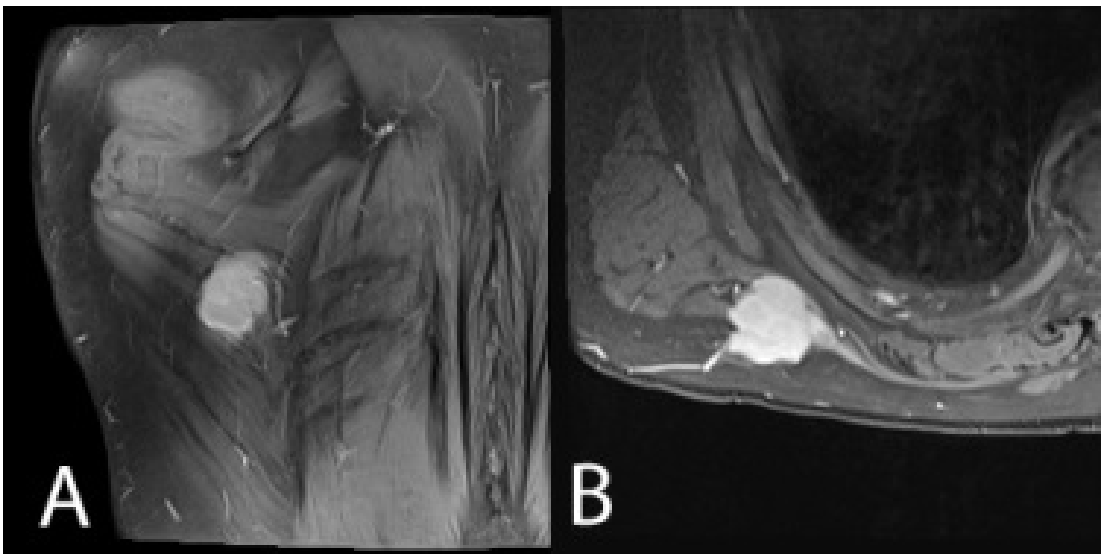

Figure 1. MRI. **A and B,** a mildly enhancing infiltrative mass centered within the inferolateral latissimus dorsi

2. Case Report

A previously healthy 63-year old male was incidentally discovered to have a “bump" on the right side of his back by his wife. There was no previous history of this malignancy. Clinically, this was thought to be a lipoma. MRI revealed a mildly enhancing 5-cm mass centered within the inferolateral right latissimus dorsi with no osseous involvement [**Figure 1**]. Retrospectively, a prior CT scan done after an accident had shown a smaller mass (3 cm) in the same location but this did not raise concern at the time. However, the fact that the mass appeared to be enlarging raised suspicion for sarcoma this time around.

A fine needle biopsy (FNA) was performed and showed a cellular smear containing clusters and single atypical hyperchromatic cells with round to irregular nuclear contours embedded in a lipomatous background. The single

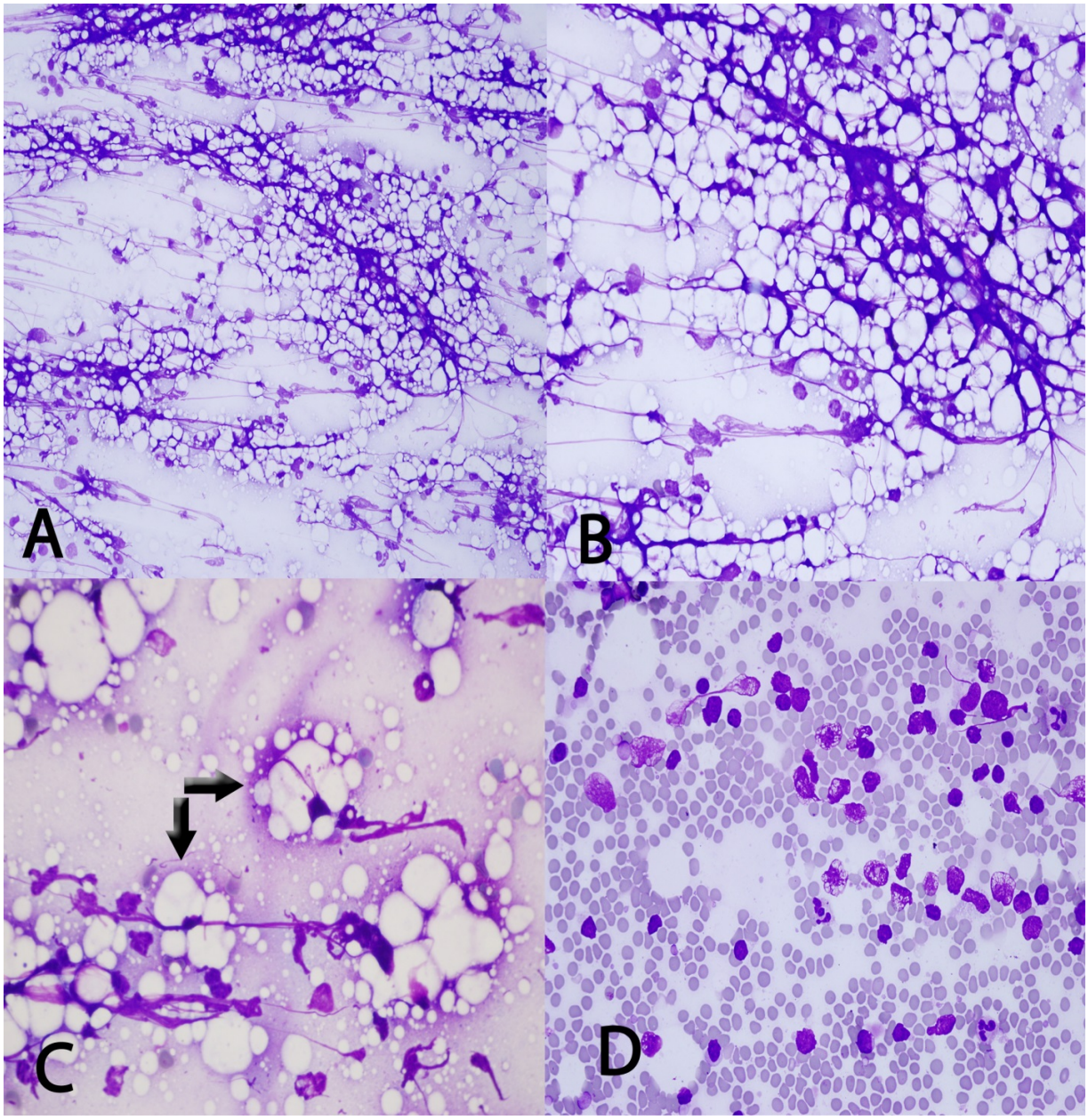

Figure 2. Fine needle aspiration. **A and B,** clusters of vacuolated cells with interspersed small round nuclei. The nuclei show fine uniform chromatin and smooth nuclear contour. **C,** high power view showing multivacuolated cells resembling lipoblasts (arrows). **D,** dispersed lymphocytes are present at the edge of the smear [A-D: Diff-Quik stain; 20x, 40x, 60x and 40x, respectively]

atypical cells showed indented nuclei associated with adipocytes that resembled "lipoblasts" [**Figure2**]. There was no adequate cell-block material for ancillary studies. The FNA was initially diagnosed as an atypical lipomatous proliferation suspicious for liposarcoma. The patient subsequently underwent definitive resection, and a 3.5 x 3 x 4 cm mass of the right latissimus dorsi was entirely submitted for microscopic evaluation.

Sections showed a cellular proliferation of medium to large lymphoid-appearing cells with open chromatin, irregular nuclear contours and prominent nucleoli, resembling centroblasts. A background of smaller centrocyte-like cleaved cells was also present. The tumor exhibited a predominantly nodular growth pattern with few areas showing a more diffuse growth. Immunohistochemical (IHC) stains performed on the cell-block material showed that the neoplastic cells were positive for CD20 and CD10, indicative of germinal center derived B-cell phenotype. The neoplastic B-cells were positive for BCL2 protein, and CD23 highlighted the background dendritic meshwork in the predominantly nodular zones. CD3 and CD5 stained background small T-cells. The proliferation rate using ki-67 was approximately 30%. FISH analysis on paraffin sections was positive for *IgH*/*BCL2* fusion in 20% of the cells but negative for *BCL6* (3q27) rearrangement.

Given the areas of diffuse growth, the overall findings were consistent with a diffuse large B-cell lymphoma of germinal center origin, likely arising from an underlying follicular lymphoma [**Figure 3**].

A staging bone marrow biopsy showed normocellular marrow with no morphologic evidence of lymphoma, and a peripheral blood smear was morphologically unremarkable as well. Positron Emission Tomography (PET) scan showed no hypermetabolic foci to suggest systemic involvement.

3. Discussion

The diagnostic utility of FNA biopsy for soft tissue masses is well-documented (Wakely & Kneisl, 2000). However, FNA biopsy is limited in its ability to assess tumor architecture, an important element for histologic diagnosis (Qian, 2014). Additionally, aspirate smears may lack enough histologic material for essential ancillary diagnostic studies. This is particularly problematic when the differential diagnosis includes the rare event of possible soft tissue involvement by lymphoma. Such cases may require re-aspiration for cell-block material, flow cytometry or even tissue biopsy for the necessary subsequent phenotypic/ genotypic studies and for further subtyping of the lymphoproliferative process.

Most cases of NHL involving skeletal muscle represent dissemination from local or regional lymphoma. Primary skeletal muscle non-Hodgkin lymphoma is rare, with the most common subtype being diffuse large B-cell lymphoma (Gao et al., 2012). Patients with diffuse large B-cell lymphoma have a propensity to present with a rapidly enlarging nodal or extra-nodal soft tissue mass with associated pain and tenderness (Meister, 1992). The overall symptoms of soft tissue lymphoma are not specific and may mimic other malignant soft tissue tumors (Gao et al., 2012). Additionally, the diagnosis of musculoskeletal lymphoma is difficult to make using imaging criteria because the presentation overlaps both clinically and radiologically with that of soft tissue sarcoma (Meister, 1992; Malloy et al., 1992). One of the radiologic features of soft tissue lymphoma is local extension of the tumor with preservation of the surrounding structures (Derenzini et al., 2013).

On FNA, lymphomas will show a uniform population of discohesive lymphocytes with high nuclear: cytoplasmic ratio, large vesicular nuclei, obvious nucleoli and a moderate amount of cytoplasm, mixed with neutrophils and small lymphocytes (Qian, 2014). Lipomas, on the other hand, show univacuolated adipocytes of uniform size with small round nuclei and evenly distributed chromatin (Qian, 2014; Akerman & Rydholm, 1987; Walaas & Kindblom, 1985). Atypical lipomatous tumors exhibit lipid vacuoles of varying size, atypical stromal nuclei and lipoblasts (Nemanqani & Mourad, 1999).

In this case, the smears demonstrated a large number of vacuolated cells in the background, which were suspicious for an atypical lipomatous neoplasm. Scattered lymphocytes were also present at the periphery. The excision specimen showed lymphoma cells, at the periphery of the mass, infiltrating adipose tissues. We believe that the admixture of atypical lymphocytes with adipocytes gave the cytology smears the appearance of an atypical lipomatous tumor.

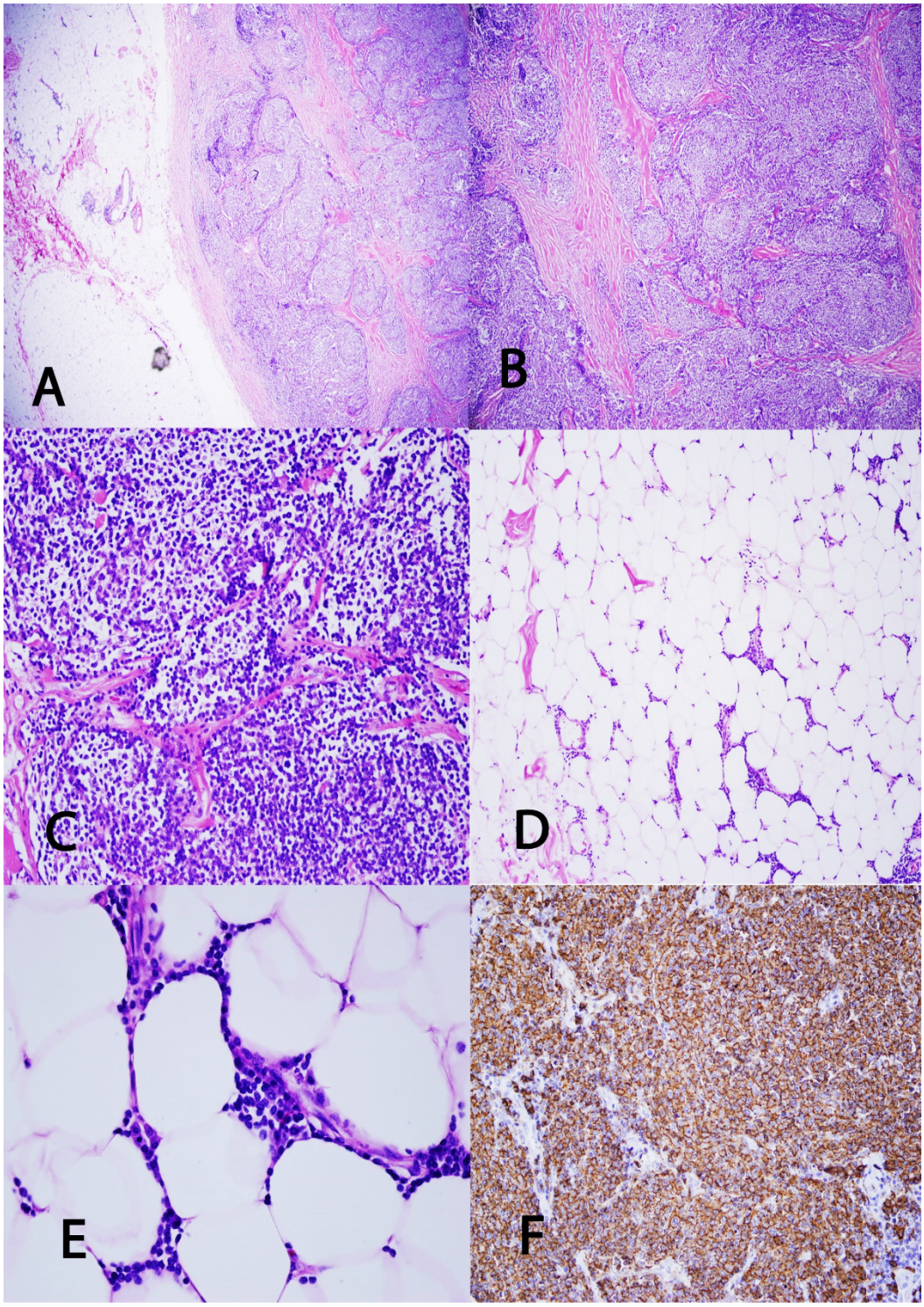

Figure 3. Resection specimen. **A,** low power view of a well-circumscribed mass with adjacent adipose tissue. **B,** atypical lymphoid proliferation composed of ill-defined nodular lymphoid aggregates separated by dense hyalinized stroma. The lymphoid aggregates are irregular in size and shape. **C,** the tumor is composed of medium-sized lymphocytes with irregular contours. **D and E,** adjacent fat showing infiltration by atypical lymphocytes. **F,** CD20 stain showing strong and diffuse positivity and confirming B cell origin of the neoplasm. [A through E, hematoxylin and eosin stain, 2x, 4x, 40x, 10x and 40x respectively; F, immuno-histochemical stain, 20x]

4. Summary

Soft tissue lymphomas are rare and, when presenting as a soft tissue mass, they may be mistaken for other tumors, an atypical lipomatous proliferation tumor in this case. Specifically, lymphocytes entrapped in fat can resemble "lipoblasts" which is a potential pitfall when evaluating soft tissue masses with a prominent lymphocytic component. Attention to the following points may be helpful in these cases:

A- Clinical-pathologic correlation with attention to radiologic features is recommended in assessing soft tissue lesions. In this case, the radiology report did not recognize any fatty characteristics for the mass, which would argue against an atypical lipomatous tumor.

B- Careful screening of the smears for atypical lymphoid cells is essential. Retrospectively, there were scattered atypical lymphocytes found at the periphery of the smear that were not associated with fat.

C- Adequate cell-block or core biopsy material is important in the evaluation of soft tissue tumors allowing for ancillary studies.

References

Akerman, M., & Rydholm, A. (1987). Aspiration cytology of lipomatous tumors: A 10-year experience at an orthopedic oncology center. *Diagn Cytopathol., 3*(4), 295-302. http://dx.doi.org/10.1002/dc.2840030407

Chan, J. (2003). Lymphoid, myeloid and histiocytic neoplasms involving soft tissues. In M. Miettinen (Ed.), *Diagnostic soft tissue pathology* (pp. 505-562). London: Churchill Livingstone.

Damron, T. A., Le, M. H., Rooney, M. T., Vermont, A., & Poiesz, B. J. (1999). Lymphoma presenting as a soft tissue mass (A soft tissue sarcoma simulator). *Clin Orthop Relat Res., 360*, 221-30. http://dx.doi.org/10.1097/00003086-199903000-00026

Derenzini, E., Casadei, B., Pellegrini, C., Argnani, L., Pileri, S., & Zinzani, P. L. (2013), Non-hodgkin lymphomas presenting as soft tissue masses: a single center experience and meta-analysis of the published series. *Clin Lymphoma Myeloma Leuk, 13*(3), 258-65. http://dx.doi.org/10.1016/j.clml.2012.10.003

Gaitonde, S., Patel, R., Alagiozian-Angelove, V., Kadkol, S., & Peace, D. (2008). Primary low grade follicular lymphoma of cranial vault mimicking lipoma at presentation. *Acta Oncol., 47*(2), 326-9. http://dx.doi.org/10.1080/02841860701558856

Gao, Y. H., Xu, Q., Wei, G., Liu, H. S., Wu, X., Liu, L. H., ... Diao, L. P. (2012). Primary giant lymphoma of the right thigh: A case report and brief review of the literature. *Oncol Lett., 4*(5), 1023-1026.

Malloy, P. C., Fishman, E. K., & Magid, D. (1992). Lymphoma of bone, muscle and skin: CT findings. *AJR Am J Roentgenol, 159*, 805-809. http://dx.doi.org/10.2214/ajr.159.4.1529847

Meister, H. P. (1992). Malignant lymphomas of soft tissues. *Verh Dtsch Ges Pathol., 76*, 140-5.

Nemanqani, D., & Mourad, W. A. (1999). Cytomorphologic features of fine-needle aspiration of liposarcoma. *Diagn Cytopathol., 20*(2), 67-69. http://dx.doi.org/10.1002/(SICI)1097-0339(199902)20:2<67::AID-DC4>3.0.CO;2-D

Qian, X. (2014). Soft Tissue. In E. Cibas & B. Ducatman (Eds.), *Cytology diagnostic principles and clinical correlates* (pp. 473-480). Philadelphia: Elsevier.

Salamao, D. R., Nascimento, A. G., Lloyd, R. V., Chen, M. G., Habermann, T. M., & Strickler, J. G. (1996). Lymphoma in soft tissue: a clinicopathologic study of 19 cases. *Hum Pathol., 27*(3), 253-7. http://dx.doi.org/10.1016/S0046-8177(96)90065-9

Travis, W., Banks, P., & Reiman, H. (1987). Primary extranodal soft tissue lymphoma of the extremities. *Am J Surg Pathol, 11*, 359-366. http://dx.doi.org/10.1097/00000478-198705000-00004

Wakely, P. Jr, & Kneisl, J. S. (2000). Soft tissue aspiration cytopathology. *Cancer, 90*(5), 292-8. http://dx.doi.org/10.1002/1097-0142(20001025)90:5<292::AID-CNCR5>3.0.CO;2-8

Wakely, P. Jr, Frable, W. J., & Kneisl, J. S. (2001). Soft tissue aspiration cytopathology of malignant lymphoma and leukemia. *Cancer, 93*(1), 35-9. http://dx.doi.org/10.1002/1097-0142(20010225)93:1<35::AID-CNCR9005>3.0.CO;2-2

Walaas, L., & Kindblom, L. G. (1985). Lipomatous tumors: A correlative. cytologic and histologic study of 27 tumors examined by fine needle aspiration cytology. *Hum Pathol., 16*(1), 6-18. http://dx.doi.org/10.1016/S0046-8177(85)80208-2

Yang, J., Zhang, F., Fang, H., Ye, Z., Lin, S., & Han, A. (2010). Clinicopathologic features of primary lymphoma in soft tissue. *Leuk Lymphoma, 51*, 2039-2046. http://dx.doi.org/10.3109/10428194.2010.520049

Copyrights

Copyright for this article is retained by the author(s), with first publication rights granted to the journal.

This is an open-access article distributed under the terms and conditions of the Creative Commons Attribution license (http://creativecommons.org/licenses/by/3.0/).